

Pathogenic Mechanisms of Takotsubo Cardiomyopathy or Broken Heart Syndrome

Devorah Leah Borisute

Devorah Leah Borisute is graduating June 2018 with a B.S. in Biology and will be attending the SUNY Downstate Physician Assistant Program.

Abstract

Takotsubo Cardiomyopathy (TTC) is a temporary heart-wall motion abnormality with the clinical presentation of a myocardial infarction. Found predominantly in postmenopausal women, TTC most often appears with apical ballooning and mid-ventricle hypokinesis. Often induced by an emotional or physical stress, TTC is reversible and excluded as a diagnosis in patients with acute plaque rupture and obstructive coronary disease. The transient nature and positive prognosis of this cardiomyopathy leaves a dilemma as to what precipitates it. This paper explores the theories of the pathogenesis of TTC including coronary artery spasm, microvascular dysfunction, and catecholamine excess. A thorough analysis of the pathogenesis was conducted using online databases. The coronary artery spasm theory involves an occlusion of a blood vessel caused by a sudden vasoconstriction of a coronary artery. This condition was confirmed in some patients with TTC using provocative testing, but failure to induce a coronary artery spasm in many patients led to its dismissal as a primary pathogenic mechanism. It is however a significant occurrence in patients with TTC and cannot be dismissed entirely. The microvascular dysfunction theory is challenged in the limited and underdeveloped methods of testing for its presence. However, using the corrected Thrombolysis in Myocardial Infarction frame count method to evaluate the flow of contrast in coronary arteries, researchers were able to indicate diffuse impaired coronary microcirculation in the myocardium. The theory involving catecholamines is based on the catecholamine surge that many patients experience with emotional or physical stressors. The stressor leads to excitation of the postsynaptic sympathetic neuron and the adrenal medulla, stimulating an influx of norepinephrine and epinephrine and the resulting hypokinesis of the apical portion of the left ventricle. Further research focused on this theory discovered the protective nature of estrogen against the catecholamine surge, explaining the prevalence of TTC in post-menopausal women. Genetic research perpetuates this theory by presenting predisposed genetic factors that prevent TTC. Analysis of the three theories found the catecholamine theory to be the most probable mechanism behind TTC, but further research is necessary to confirm TTC pathogenesis.

Introduction

Background

The cardiovascular system encompasses the extensive network that supplies the body with the nutrients and oxygen it needs to function. At the center of this complex system, the heart serves as an anatomical pump to push the blood out of its chambers and throughout the body. The sinoatrial node stimulates the cardiac muscle to contract periodically, and its normal rhythm can be measured on an electrocardiogram (ECG). In the presence of cardiac dysfunction, this test can indicate specific abnormalities in the sinus rhythm. The left ventricle is the heart's main pumping chamber, and a weakening or abnormality in its function can produce severe repercussions. There are multiple causes of left ventricular dysfunction. In the case of Takotsubo cardiomyopathy (TTC), sources like coronary artery spasm, microvascular dysfunction, and catecholamine excess are suspected to contribute to its pathogenesis (Komamura, et al. 2014). These theories are evaluated and debated in many recent studies that seek to discover the likely origin and development of TTC.

The syndrome was first described in 1990 by a Japanese cardiologist which prompted its name, Takotsubo cardiomyopathy (Sato, et al. 1990). Translated from Japanese to "octopus trap", takotsubo describes the shape of the left ventricle during systole in many patients suffering from TTC. Resembling its namesake's rounded bottom and narrow neck, TTC most commonly appears with apical ballooning and mid-ventricle hypokinesis. TTC is also known as stress-induced cardiomyopathy, ampulla cardiomyopathy, transient left ventricular apical ballooning, and broken heart syndrome. The latter title indicates the likely

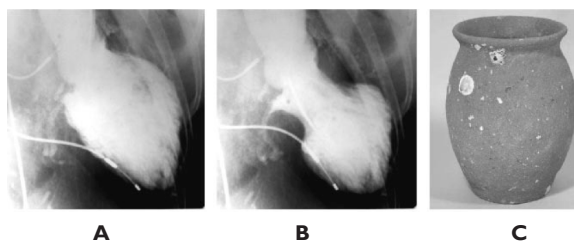


Figure 1. Left ventriculogram exhibiting Takotsubo. A: end-diastolic phase; B: end-systolic phase. Here, the apex shows akinesia with visible hypercontraction of the basal portion. C: Takotsubo, an octopus trap. (Akashi, et al. 2008)

presence of an emotional or physical trigger that precipitates the condition. Researchers found stressors such as the sudden death of a loved one, anxiety over a family member's congenital disorders, and vigorous excitement to be responsible for the onset of TTC in some of their subjects (Tsuchihashi, et al. 2001). There are instances where no physical or emotional stressor is indicated and the trigger is unknown (Gianni, et al. 2006).

Epidemiology

This specific cardiomyopathy is a relatively new diagnosis with the number of published cases growing in the past 20 years. The condition occurs predominantly in postmenopausal women which lends to one of the pathogenic theories of TTC regarding lack of estrogen and its effects on catecholamine levels in the body (Komamura, et al. 2014). A study found a 6.3-fold higher incidence of the condition in women than in men, differing

Pathogenic Mechanisms of Takotsubo Cardiomyopathy or Broken Heart Syndrome

from the usual male dominance in coronary artery diseases (Tsuchihashi, et al. 2001). A systematic review of 14 studies found that 88.8% of TTC patients were women, leaving significant room for a pathogenic mechanism that can explain the specific epidemiology of TTC.

Clinical Manifestations

Takotsubo cardiomyopathy's most common symptomatic presentation includes severe chest pain and dyspnea, resembling the symptoms of an acute myocardial infarction (Komamura, et al. 2014). Where myocardial infarctions are generally preceded by atherosclerosis, plaque buildup in arteries, TTC is excluded as a diagnosis in patients that present with artery blockage or a history of obstructive coronary artery disease. A study found 90% of its subjects without preceding conditions admitted to chest pain or discomfort with the onset of TTC (Tsuchihashi, et al. 2001). Serum level indication using cardiac biomarkers found creatine kinase and troponin T to be elevated in many cases, indicating a heart muscle abnormality. Creatine kinase expressed in cardiac muscle is used to assay damage to the heart in various cardiac conditions. In TTC, there is a slight elevation from the normal 22-198 IU/l (Tsuchihashi, et al. 2001). Troponin T, a cardiac protein released when the heart muscle is damaged, is found to be similarly elevated (Gianni, et al. 2006). In 86.5% of patients with TTC, left ventricular ejection fraction was reduced to $40.7 \pm 11.2\%$ from its normal 55% or higher. Studies also note increased left ventricular end-diastolic pressure in 93% of patients with this condition (Templin, et al. 2015) (Tsuchihashi, et al. 2001).

Diagnosis

According to Heart Failure Association's diagnostic criteria, patients need to fulfill the following specifications for their condition to be classified as TTC. The first is the presence of a wall motion abnormality involving the dyskinesis, hypokinesis or akinesis of the left ventricle mid segments. This includes the ballooning of the apex as it fails to contract. Echocardiograms or cardiac ventriculography can be used to identify this cardiomyopathy (Abe, et al. 2003). In addition, TTC is indicated only in the absence of obstructive coronary disease and acute plaque rupture and can be determined using angiographic images of the coronary arteries. This exclusion differentiates TTC from a myocardial infarction, a heart attack, which is caused by acute plaque ruptures and presents with similar symptoms. The third criteria for the diagnosis includes the appearance of new, reversible sinus rhythm changes on the patient's ECG. Most commonly, the condition appears with ST-segment elevation and T wave inversion (Gianni, et al. 2006). Another criterion is the significant elevation of serum natriuretic peptide (BNP or NT-proBNP), a blood indicator of heart failure. Bloodwork to assess cardiac enzyme levels like Troponin T is also used in the diagnosis of TTC. Perhaps the most important aspect of diagnosing a patient with TTC is the transient nature of

the condition. Essentially, the patient should recover full cardiac function within a week of the acute episode. If a patient does not recover full systolic function within 12 weeks, a different diagnosis should be considered (Komamura, et al. 2014).

The Mayo Clinic's diagnostic criteria includes the absence of pheochromocytoma, a hormone releasing tumor of the adrenal glands. If a patient presented with additional symptoms such as sweating, tachycardia, and headaches, pheochromocytoma was suspected (Reeder, Prasad, 2017). However, the updated conclusive criteria released by the Heart Failure Association, allows for pheochromocytoma as a trigger for TTC in the event that it precipitates a catecholamine storm (Ansari, El-Battrawy, 2017). Mayo Clinic also addresses the exclusion of myocarditis, inflammation of the myocardium, as part of its diagnostic criteria. Myocarditis involves slower recovery than TTC and can be excluded with the absence of scarring and myocardial inflammation on cardiovascular magnetic resonance imaging (MRI). MRI also confirms the reversible wall motion abnormalities and the quantification of the ventricular function in a patient with suspected TTC.

Management

Due to its transient nature, TTC can often be managed by addressing and alleviating the physical or emotional stressors that triggered the onset of the cardiomyopathy. Although there are not any conclusive treatments, treatments generally administered for heart failure such as beta blockers, ACE inhibitors, and diuretics, are often administered as supportive care for TTC patients. A possible treatment specified for older women is estrogen administration. This was found to be beneficial in an animal model of TTC, though clinical trials have not yet been performed. The general prognosis of TTC is positive, but complications have occurred in many patients ranging from cardiogenic shock and left ventricular outflow tract obstruction, to severe systolic dysfunction. Diagnosis and management of these conditions is imperative to reduce the fatalities attributed to TTC (De Backer, et al. 2014).

Methods

The research in this paper was compiled using the online databases, Pubmed and UpToDate, and through Touro's online library system for access to databases Proquest and Ebsco. Keywords Takotsubo cardiomyopathy and Broken heart syndrome were used in the initial research of this paper. Careful analysis of the gathered material prompted further research using sources cited in articles on this topic. Both peer reviewed articles and clinical studies were analyzed to evaluate the hypothesized pathogenic mechanisms of Takotsubo cardiomyopathy.

Discussion

When evaluating the pathogenesis of TTC, researchers are faced with various differentiating origins and pathways that TTC

can develop from. A worldwide investigation of patients with TTC has led to several possible theories of the cardiomyopathy including a coronary artery spasm, catecholamine excess, and microvascular dysfunction. While studies have produced results that support all three theories, there is still a significant amount of research required to determine the definitive pathogenic mechanism of TTC.

Coronary Artery Spasm

The heart is a recipient of its own labor in its utilization of its blood supply from the coronary arteries. In order for the heart muscle to function, the correct amount of blood supply in regular increments must be delivered through these arteries. Many have hypothesized that an abnormality in this cycle is the source of TTC in the form of a coronary artery spasm. A coronary artery spasm is a temporary contracting of the wall of the artery that constricts blood flow and leads to decreased blood supply to the heart muscle. The occlusion or near occlusion of the vessel can cause decreased muscle movement in the heart chambers that depend on the regular blood supply from the coronary arteries.

Studies performed on patients with TTC support this theory. In one case study, a 79-year-old man was admitted to a hospital presenting with three consecutive days of chest pain. Echocardiography showed hyperkineses in the basal wall and akinesis in the apex of the left ventricle. In order to locate the source of the cardiomyopathy, doctors performed provocative testing using ergonovine, a muscle contractant. The diagnostic screening test induced a right coronary artery spasm and resulted in ECG changes with increased ST segment elevation in leads II, III, and aVF. The patient's normal left ventricle wall motion was restored one week later, and he was subsequently diagnosed with TTC with a pathogenesis attributed to a coronary artery spasm (Misumi, et al. 2010).

Although there are many cases of patients with TTC experiencing induced coronary artery spasm from provocative testing using either ergonovine or acetylcholine, there are more that have not. Many patients with TTC did not present with increased susceptibility to ergonovine or acetylcholine in provocative testing, and according to reports, only 30% of patients presented characteristics of a vasospasm with testing (Komamura, et al. 2014). This research leaves a substantial gap in the coronary artery spasm theory (Madias, 2014). Nonetheless, the presence of coronary vasospasm in some TTC patients cannot be ignored and this theory has therefore not been completely dismissed.

Microvascular Dysfunction

Another theory explored as a pathogenic mechanism of TTC is microvascular dysfunction. The primary obstacle in exploring this mechanism is the limited technology available to evaluate microvascular function. One study was performed using

the Thrombolysis In Myocardial Infarction (TIMI) frame count technique, a quantitative, continuous variable that assesses flow changes by counting the cineframes it takes for contrast to reach coronary landmarks. Researchers evaluated the flow of the left anterior descending artery, left circumflex artery, and the right coronary artery in order to suggest diffuse impaired coronary microcirculation in the myocardium. In 23 of the 24 patients studied, there was a slowdown in coronary microcirculation noted (Fazio, et al. 2010). A more recent assessment pointed out that the akinesis in the left ventricles of those patients was too large of an area to be attributed to the dysfunctional microvessels' supply (Vitale, et al. 2016). A corrected TIMI frame count was performed and found that the flow was slower in the left anterior descending artery and the researchers suggested this being the source of akinesis in the apex while the base is relatively spared in TTC (Khalid, et al. 2015). However, the combined studies do not find microvascular dysfunction to be the primary source of TTC, but it is likely to play a role in the etiopathogenesis.

Catecholamine Theory

The catecholamine theory is perhaps the most well developed and significant theory of TTC. Many patients are noted to have grossly elevated plasma catecholamine levels, measuring at two to three times greater than in patients with myocardial infarctions and twenty times higher than normal adults (Zeb, et al. 2011). These elevations were noted of both adrenomedullary and sympathoneurally-derived catecholamines. The adrenal medulla releases epinephrine and norepinephrine after stress, which activates preganglionic sympathetic nerves. In addition, the peripheral sympathetic nerves release norepinephrine, both of which contribute to the β -adrenergic pathway. The common emotional or physical stressor in patients is tightly connected with this theory in its influx of catecholamines. Researchers concluded that the stressor induced hyperactivity of the sympathetic nervous system and prompted the release of catecholamines into the patient's blood stream (Tarkin, et al. 2008).

The apex of the left ventricle has higher adrenoceptor density than the base, presenting location specific evidence for the cardiomyopathy. The influx of catecholamines, both epinephrine and norepinephrine, are directed to the β -adrenergic pathway. This pathway is specifically located at the apex of the left ventricle, likely to produce the heart's fight or flight response of hypercontraction of the cardiomyocytes. The β -adrenergic receptors in the cell membranes bind to the catecholamines which ignites this response. The overstimulation of Gs (activator) through β_2 -coupling due to catecholamines can cause apoptosis of the myocytes. The process therefore switches to Gi (inhibitor) to protect the myocytes from further damage. This causes a decrease in contraction and results in the hypokinesis of the apex of the left ventricle. There is serum evidence

Pathogenic Mechanisms of Takotsubo Cardiomyopathy or Broken Heart Syndrome

of slight necrosis caused by the excess catecholamine in the minimally elevated troponin levels in patients with TTC. Studies showed that a signaling pathway known to exhibit anti-apoptosis functions, phosphatidylinositol 3-kinase protein kinase B, presented increased activity. This may be the source of the quick recovery of the myocytes. In addition to this, the transient nature of this condition can be attributed to the inverse switch from Gi to Gs resulting in the expeditious recovery of systolic function in patients (Nef, et al. 2009).

Another theory on the rapid recovery of the myocytes is related to stem cells. A study using *in vivo* and *in vitro* cardiomyocytes and cardiac stem cells found that the cardiac stem cells were resistant to neurohumoral overstimulation. Researchers injected male Wistar rats with isoproterenol and noted left ventricle dysfunction in the subjects. The left ventricular function began to improve on day three post isoproterenol stimulation. β -adrenoreceptor hyperactivity from the catecholamine stimulation leads to PKA-mediated hyperphosphorylation of the ryanodine receptor 2, a calcium channel that mediates the release of Ca^{2+} from the sarcoplasmic reticulum to the cytoplasm. This hyperphosphorylation causes Ca^{2+} leakage which, in turn, produces myocyte damage. The cardiac stem cells have low levels of β -adrenergic receptors and do not express ryanodine receptor 2. This explains the resistance cardiac stem cells possess to the catecholamine overstimulation and the regeneration of cardiomyocytes that restore normal left ventricle function (Ellison, et al. 2007).

There is research that suggests specifically local release of catecholamines are at play in TTC. This is based on the findings in a study performed on blood samples from both the aortic root and coronary sinus of patients with the condition. Catecholamine concentration was found to be higher in the coronary sinus signaling excessive local catecholamine release from the heart (Kume, et al. 2008).

Besides for emotional stressors, catecholamine excess resulting in TTC is precipitated by other factors like acute brain injury or treatment of respiratory distress. A study done on patients with subarachnoid hemorrhage reports of eight patients developing TTC as a result of a brain aneurysm rupture. Researchers theorize that at the time of the event, patients experience a catecholamine surge which can mediate cardiopulmonary dysfunction (Franco, et al. 2010). A case report presenting a patient with acute asthma exacerbation who was treated with β -2 agonist nebulization and intravenous aminophylline. After fourteen hours of treatment she complained of shortness of breath and pain in her jaw. Testing showed classic TTC with ST segment elevation, T wave inversion, and left ventricular apical akinesia. The treatment was immediately stopped and replaced with ipratropium nebulization and intravenous corticosteroids. After 48 hours the echocardiogram revealed full recovery. Additional studies report that methylxanthines, the structural classification of aminophylline, stimulate the release of catecholamines

from the adrenal medulla and of norepinephrine from cardiac β -adrenergic nerve endings (Khawaja, Tai, 2016). Another study reports a similar case with a patient treated with nebulized adrenaline to manage an airway obstruction. Like the previous case study, this patient developed TTC post adrenaline treatment (Keshtkar, et al. 2016). These reports present a medication administration that possibly caused a catecholamine surge suspected to have induced the patients' TTC.

While the catecholamine theory is the most developed and scientifically supported mechanism of TTC, not all patients are found to have elevated catecholamine levels, prompting continued investigation into a definitive pathogenesis of the condition (Tarkin, et al. 2008).

Low Estrogen Levels

The occurrence of TTC specifically in post-menopausal women prompted the investigation of estrogen deficiency as a predisposing factor. One study demonstrated increased estrogen serum levels in rats weakened cardiac changes in response to immobilization stress. P44/p42 mitogen-activated protein kinase was activated by the immobilization stress along with the upregulation of immediate early genes in the myocardium. Immediate early genes are activated in response to cellular stimuli at the transcription level. The study theorizes that estrogen attenuated this process and inhibited the activation of the sympathetic nervous system by decreasing the formulation of immediate early genes in both the brain and heart (Ueyama, 2004). In a study published by this author more recently, it was determined that, in response to immobilization stress, ovariectomized rats that received estradiol did not experience a significant decrease in left ventricular contraction. The ovariectomized exposed to stress sans estradiol treatment did, however, experience percentage contraction reduction (Ueyama, et al. 2003). An evaluation of women with TTC found that majority of the patients were post-menopausal and had not undergone estrogen replacement therapy. Researchers postulated that lack of estrogen replacement therapy may predispose women to TTC (Kuo, et al. 2010). Combined, these studies propose that post-menopausal women, who experience a deficiency of estrogen, lack a protective barrier against the development of TTC.

Genetic Predisposition and the Catecholamine Theory

With analysis, the catecholamine theory appears problematic because not all patients experience this cardiac dysfunction with an emotional or physical stressor that may cause a catecholamine surge. Genetic research introduced new theories that address this dilemma.

The apparent exclusiveness of patients who develop TTC suggests that the general population possesses a molecular mechanism that protects their cardiomyocytes from a catecholamine

surge and prevents necrosis. Bcl2-associated athanogene 3 (BAG3) is a constituent of an autophagy pathway and one that allows for the degradation of intracellular components. A study found that it is expressed in response to various stressors and is therefore theorized to promote stress resistance. The ablation of BAG3 in mice resulted in lethal cardiomyopathy shortly postnatal. The study found that BAG3 single-nucleotide polymorphisms resulted in TTC. It introduced a novel post-transcriptional pathway that, in response to epinephrine treatment, leads to BAG3 expression. Micro-RNAs are fundamental in their role as repressors of messenger RNAs' translation. The study describes miR-371a-5p, a pathway that binds miRNA to 3'-untranslated region (3'-UTR) of the BAG3 gene. Epinephrine induces miR-371a-5p which leads to BAG3 upregulation in cardiomyocytes. However, this protective mechanism is lost in patients who possess a single nucleotide variant involving the 3'-UTR in the BAG3 gene which alters the miR-371a-5p pathway and eliminates its binding. This genetic variant of BAG3 is found in many patients with TTC and could explain the cardiac dysfunction post catecholamine (D'avenia, et al. 2015).

Further research into the catecholamine mechanism produced an underlying theory involving another genetic role in TTC. The study concluded that genetic susceptibility involving β -adrenergic signaling increased the risk of toxicity induced by catecholamines in TTC.

Researchers utilized technology involving the reprogramming of somatic cells into induced pluripotent stem cells (iPSC) to produce this conclusion. Reprogramming somatic cells of these patients allowed for differentiation into cardiomyocytes that could be experimented on.

The study involved healthy donors for controls and patients with TTC. The somatic cells of the Takotsubo patients were reprogrammed and expanded into high quality iPSC clones. Using Wnt modulation and metabolic selection, cells were then differentiated into cardiomyocytes (CMs). After three months, the iPSC-CMs were subjected to isoprenaline or epinephrine in order to replicate the catecholamine stimulation suspected to be experienced in patients with TTC. After analysis, studies showed that the catecholamine excess in the TTC iPSC-CMs was apparent in the increased expression of NR4A1, a cardiac stress-related gene. Compared to the control iPSC-CMs, the TTC iPSC-CMs recorded much greater expression of NR4A1 post subjection to catecholamines. Three weeks after catecholamine administration, there was a reversal in changes to the NR4A1 expression.

The researchers proceeded to investigate β -adrenergic signaling using the TTC iPSC-CMs. They measured cAMP levels and PKA activation by phosphorylation and found increased levels in both compared to the control iPSC-CMs after catecholamine treatment. In addition, extracellular signal-regulated kinase was phosphorylated maximally in the TTC iPSC-CMs after

epinephrine or isoprenaline treatment where the controls were significantly reduced in comparison. Increased lipid accumulation was also noted in catecholamine treated TTC iPSC-CMs.

Researchers examined the electrical activity of catecholamine treated iPSC-CMs from patients with TTC and found that more than half were silenced under certain isoprenaline concentrations where only some of the controls were. For those that were not silenced, beating frequency was significantly increased in the TTC iPSC-CMs in comparison to the control subjects. The changes to the electrical activity was reversed following washout of the isoprenaline after 24 hours.

Additionally, the study found that engineered heart muscles using the TTC iPSC-CMs presented an impaired force of contraction. Muscles also presented a higher sensitivity compared to control subjects to isoprenaline-stimulated inotropy, an altering of the force of muscle contractions. Further investigation into the genetic makeup of the patients with TTC found variants in some patients' genes that are key regulators of cardiac function. These findings may contribute to the hypothesis of a predisposition to TTC, specifically involving catecholamine toxicity (Borchert, et al. 2017).

Conclusion

The pathogenesis of TTC is an evolving phenomenon with developing theories. While coronary artery spasm is found in some patients with TTC, the majority failed to experience induced coronary artery spasm with provocative testing. Microvascular dysfunction is a challenge to evaluate, but it has been found to be a contributing factor in many patients with TTC, though it is likely not the primary cause. Of the three theories presented, the catecholamine excess theory, supported by genetic research, and the estrogen deficiency theory is the most well developed pathogenic mechanism. In order to understand this cardiomyopathy in its entirety and to produce an appropriate treatment, more research is required involving integration of the cardiovascular, central neural, autonomic, and endocrine systems in their response to stress, and the genetic predisposition to TTC.

References

- Abe Y, Kondo M, Matsuoka R, Araki M, Dohyama K, Tanio H. Assessment of clinical features in transient left ventricular apical ballooning. *Journal of the American College of Cardiology*. 2003; 41(5):737-742. doi:10.1016/S0735-1097(02)02925-X
- Akashi Y, J, Goldstein D, Barbaro G, Ueyama T. Takotsubo Cardiomyopathy A New Form of Acute, Reversible Heart Failure. *Circulation*. 2008; 118:2754-2762. doi:10.1161/circulationaha.108.767012
- Ansari U, El-Battrawy I. The Clinical Manifestations, Diagnosis and Management of Takotsubo Syndrome. *Interventional Cardiology*. 2017; Chapter 11. doi: 10.5772/68037.

Pathogenic Mechanisms of Takotsubo Cardiomyopathy or Broken Heart Syndrome

- Borchert T, Hubscher D, Guessoun C, Lam T, Ghadri J, et al. Catecholamine-Dependent β -Adrenergic Signaling in a Pluripotent Stem Cell Model of Takotsubo Cardiomyopathy. *Journal of the American College of Cardiology*. 2017;70(8):975-991. doi: 10.1016/j.jacc.2017.06.061
- D'avenia, M; Citro, R; De Marco, M; Veronese, A; Rosati, A; et al. A novel miR-371a-5p-mediated pathway, leading to BAG3 upregulation in cardiomyocytes in response to epinephrine, is lost in Takotsubo cardiomyopathy. *Cell Death and Disease*. 2015; volume 6, e1948. doi: 10.1038/cddis.2015.280
- De Backer O; Debonnaire P; Gevaert S; Missault L; Gheeraert P. Prevalence, associated factors and management implications of left ventricular outflow tract obstruction in takotsubo cardiomyopathy: a two-year, two-center experience. *BMC Cardiovascular Disorders*. 2014; 14:47. doi: 10.1186/1471-2261-14-147
- Ellison GM, Torella D, Karakikes I, Purushothaman S, Curcio A, Gasparri C, Indolfi C, Cable N, Goldspink D, Nadal-Ginard B. Acute β -Adrenergic Overload Produces Myocyte Damage through Calcium Leakage from the Ryanodine Receptor 2 but Sparing Cardiac Stem Cells. *Journal of Biological Chemistry*. 2007; 282:11397e409. doi: 10.1074/jbc.M607391200
- Fazio G., Sarullo F.M., Novo G. Evola S, Lunetta M. Tako-tsubo cardiomyopathy and microcirculation. *Journal of Clinical Monitoring and Computing*. 2010;24(2):101-105. doi: 10.1007/s10877-009-9217-5
- Franco C, Khaled B, Afonso L, Raufi M. Acute Subarachnoid Hemorrhage and Cardiac Abnormalities: Takotsubo Cardiomyopathy or Neurogenic Stunned Myocardium? a case report. *Cases Journal*. 2010;3(81): 1757. doi: 10.1186/1757-1626-3-81
- Gianni M, Dentali F, Grandi A, Sumner G, Hiralal R, Lonn E. Apical ballooning syndrome or takotsubo cardiomyopathy: a systematic review. *European Heart Journal*. 2006; 27(13):1523-1529. doi:10.1093/eurheartj/ehl032
- Keshtkar F, Dale OT, Bennett WO, Hall CE. Management of airway obstruction with nebulised adrenaline resulting in takotsubo cardiomyopathy: case report. *The Journal of Laryngology & Otology*. 2016; 130(9):883-886. doi: 10.1017/S0022215116008288
- Khalid N, Iqbal I, Coram R, Raza T, Fahsah I, Ikram, S. Thrombolysis In Myocardial Infarction
- Frame Count in Takotsubo Cardiomyopathy. *International Journal of Cardiology*. 2015; 191:107-108. doi: 10.1016/j.ijcard.2015.04.192
- Khwaja Y, Tai, J. Takotsubo cardiomyopathy with use of salbutamol nebulisation and aminophylline infusion in a patient with acute asthma exacerbation. *BMJ Case Reports*. 2016. doi: 10.1136/bcr-2016-217364
- Komamura K, Fukui M, Iwasaku T, Hirotsu S, Masuyama T. Takotsubo cardiomyopathy: Pathophysiology, diagnosis and treatment. *World Journal of Cardiology*. 2014;6(7):602-609. doi: 10.4330/wjc.v6.i7.602
- Kume T, Kawamoto T, Okura H, Toyota E, Neishi Y, Watanabe N, Hayashida A, Okahashi A, Yoshimura Y, Saito K, Nezu S, Yamada R, Yoshida K. Local Release of Catecholamines From the Hearts of Patients With Tako-Tsubo-Like Left Ventricular Dysfunction. *Circulation Journal*. 2008;72(1):106-108. doi: 10.1253/circj.72.106
- Kuo B, Choubey R, Novaro G. Reduced estrogen in menopause may predispose women to takotsubo cardiomyopathy. *Gender Medicine*. 2010; 7(1):71-77. doi: 10.1016/j.genm.2010.01.006.
- Madias J. Coronary vasospasm is an unlikely cause of Takotsubo syndrome, although we should keep an open mind. *International Journal of Cardiology*. 2014;176(1):1-5. doi: 10.1016/j.ijcard.2014.06.069
- Misumi I, Ebihara K, Akahoshi R, Hirota Y, Sakai A, Sanjo M, Takanaga M, Ueda K. Coronary spasm as a cause of takotsubo cardiomyopathy and intraventricular obstruction. *Journal of Cardiology Cases*. 2010;2(2):83-87. doi: 10.1016/j.jccase.2010.03.007
- Nef, H. M., Möllmann, H., Hilpert, P., Troidl, C., Voss, S., Rolf, A., Behrens, C. B., Weber, M., Hamm, C. W. and Elsässer, A. Activated cell survival cascade protects cardiomyocytes from cell death in Tako-Tsubo cardiomyopathy. *European Journal of Heart Failure*. 2009; 11: 758-764. doi: 10.1093/eurjhf/hfp076
- Reeder G; Prasad A. Clinical manifestations and diagnosis of stress (takotsubo) cardiomyopathy. *Post TW, ed. UpToDate*. Waltham, MA: UpToDate Inc. Update Jan, 2018
- Sato H, Tateishi H, Uchida T. Takotsubo-type cardiomyopathy due to multivessel spasm. In: Kodama K, Haze K, Hon M, editors. *Clinical Aspect of Myocardial Injury: From Ischemia to Heart Failure*. Tokyo, Japan: Kagakuhyoronsha; 1990. pp. 56-64.
- Tarkin, Jason M; Khetyar, Maher; Kaski, Juan C. Management of Tako-tsubo Syndrome. *Cardiovascular Drugs and Therapy*. 2008;22(1):71-77. doi: 10.1007/s10557-007-6074-7
- Templin C, Ghadri J, Lüscher T, et al. Clinical Features and Outcomes of Takotsubo (Stress) Cardiomyopathy. *The New England Journal Of Medicine*. September 3, 2015;373(10):929-938. doi: 10.1056/NEJMoa1406761
- Tsuchihashi T, Ueshima K, Uchida T, Oh-mura N, Kimura K, Owa M, Yoshiyama M, Miyazaki S, Haze K, Ogawa H, Honda T, Hase M, Kai R, Morii I. Transient left ventricular apical ballooning without coronary artery stenosis: a novel heart syndrome mimicking acute myocardial infarction. *Journal of the American College of Cardiology*. 2001;38(1):11-18. doi: 10.1016/S0735-1097(01)01316-X
- Ueyama T, Hano T, Kasamatsu K, Yamamoto K, Tsuruo Y, Nishio I. Estrogen attenuates the emotional stress-induced cardiac responses in the animal model of Tako-tsubo (Ampulla) cardiomyopathy. *Journal of Cardiovascular Pharmacology*. 2003;42(Suppl 1):117-S119.

Devorah Leah Borisute

Ueyama, T. Emotional Stress-Induced Tako-tsubo Cardiomyopathy: Animal Model and Molecular Mechanism. *Annals of the New York Academy of Sciences*. 2004; 1018: 437–444. doi: 10.1196/annals.1296.054

Vitale C, Rosano G, Kaski J. Role of Coronary Microvascular Dysfunction in Takotsubo Cardiomyopathy. *Circulation Journal*. 2016;80(2):299-30. doi: 10.1253/circj.CJ-15-1364

Zeb M, Sambu N, Scott P, Curzen N. Takotsubo cardiomyopathy: a diagnostic challenge.

Postgraduate Medical Journal. 2011;87(1023):51. doi: 10.1136/pgmj.2010.102475